


REVIEW

Diagnostic Salivary Gland Imaging – A Review

Mohamed Abdulcader Riyaz 
Assistant Professor of Oral Medicine and Radiology
Department of Maxillofacial surgery and Diagnostic Sciences
College of Dentistry in ArRass, Qassim University

ABSTRACT

The oral and maxillofacial diagnosticians are responsible for the detection, description, differentiation and diagnosis of salivary gland disorders. The algorithm of salivary gland imaging depends on the stage of the clinical disease. For the sake of ease of description, the salivary gland disorders can be broadly divided into inflammatory, reactive and space-occupying masses. Diagnostic imaging of salivary gland disease may be useful in distinguishing diffuse involvement from focal suppurative involvement, differentiate and identify neoplastic processes from inflammatory disease, delineate ductal morphology, identify sialoliths, identify the effect of salivary gland pathology on adjacent structures, aid in the selection of biopsy sites, etc¹. This article is aimed at reviewing the different imaging modalities and the current protocol of salivary gland imaging for different clinical situations.

KEYWORDS: Salivary gland imaging, ultrasonography, sialendoscopy.

Correspondence: Mohamed Abdulcader Riyaz, College of Dentistry in ArRass, Qassim University, Al Qassim, Saudi Arabia.
Email: riyazdental@gmail.com

Copyright © 2020 Riyaz MA. This is an open access article distributed under the [Creative Commons Attribution 4.0 International](https://creativecommons.org/licenses/by/4.0/), which permits unrestricted use, distribution, and reproduction in any medium, provided the original work is properly cited.

INTRODUCTION

The salivary glands are exocrine in nature and are classified into major and minor salivary glands. The major salivary glands are a pair of parotid glands, submandibular glands and sublingual glands. The minor salivary glands are located in the palate, labial mucosa, tongue, buccal mucosa and floor of the mouth². The parotid gland is the first to develop followed by submandibular gland and finally the sublingual gland. Proliferation of the oral epithelium is responsible for the formation of the parenchyma (secretory unit) of the parotid gland. Stroma of the gland (capsule and the septae) originates from the mesenchyme or could be neural crest in origin. The parotid gland becomes encapsulated after submandibular and sublingual gland, after the development of the lymphatic system. The parotid gland is the commonest site for salivary gland lymphomas. The parotid gland is located behind the angle of the mandible with the anterior part of the gland lying on the masseter muscle. It has a large single duct (Stenson's) that runs forwards crossing the masseter muscle, turning inwards at its anterior border to pierce the Buccinator muscle and then opening into the mouth on a papilla opposite the second upper molar tooth. At its anterior margin, there is a small accessory part between the duct and the zygomatic arch. The seventh cranial nerve (facial nerve) branches roughly divide the parotid gland into superficial lobes and the deep lobes while coursing anteriorly from the stylomastoid foramen to the muscles of facial expression. The Submandibular gland is located below the mandible and has superficial part that lies on the

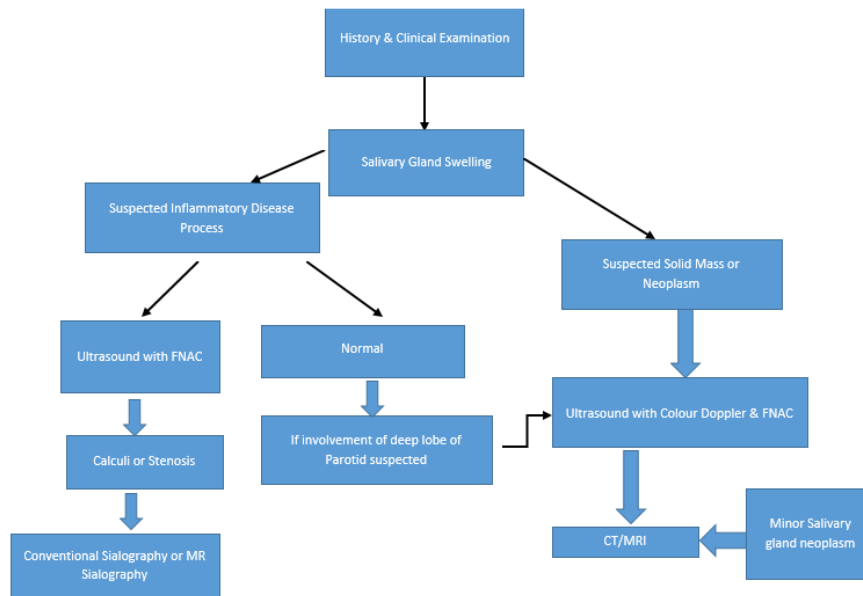
mylohyoid muscle and deep part that extends deep to the posterior border of this muscle. A single duct (Wharton's) emerges from deep surface of the gland, turns around the posterior border of the mylohyoid muscle and runs deep to that muscle to open on a papilla at the side of the frenulum beneath the tongue. The sublingual gland lies anteriorly in the floor of the mouth and opens into the mouth through a number of ducts (Ducts of Rivinus). Ducts through all of these glands are evenly distributed and gently tapered³. In this narrative review, various imaging modalities utilized in salivary gland visualization are discussed. The imaging modalities included in this review are analyzed based on their role in the initial diagnostic categorization and preoperative planning of salivary gland diseases. All the imaging modalities except Positron Emission Tomography (PET) are included in this review. PET does not have much role in the initial diagnostic categorization considering the amount of radiation involved for the amount of information obtained. PET/CT is useful only after the salivary gland disease is categorized as a malignancy for further staging and to rule out secondaries.

IMAGING MODALITIES

The imaging modalities are helpful to have a better insight and orientation about salivary gland disorders. They are useful adjuncts to clinical examination for diagnosing salivary glandular pathology. The following are the imaging modalities used for salivary gland imaging:

1. Plain Film Radiography

2. Sialography
3. Ultrasonography
4. Computed tomography (CT)
5. Magnetic Resonance Imaging (MRI)
6. Sialendoscopy.

Flowchart 1: Clinical algorithm for Salivary Gland Imaging

Plain Film Radiography: Plain film radiography gives two dimensional information about three dimensional objects, but, object localization techniques like right angled technique helps in viewing the pathology in two different angulations giving an idea about the third dimension. However, with plain film radiography, the overlapping of anatomic structures around the region of interest cannot be avoided. The plain radiographic techniques for parotid gland are Puffed cheek Antero-posterior (AP) view, buccal soft tissue intraoral radiograph, Lateral oblique (Ramus-Condyle) view. The radiographic techniques for submandibular/sublingual gland are Lateral oblique view with the tongue depressed, mandibular occlusal view and over the shoulder occlusal projection view⁴.

Sialography: It's a radiographic examination of the salivary glands (Parotid and Submandibular gland) and ducts using contrast media. Cannulation of sublingual glands is almost impossible and it may get accidentally infused with contrast media while cannulating the submandibular gland duct. So, it's important to give a 45 degree angulation to the lacrimal probe and cannulas while cannulating submandibular gland to avoid accidentally infusing the sublingual gland. In addition to the plain projection radiographic images, the opacified gland can be viewed by CT and MRI. CT and MRI provides three dimensional information of the ductular morphology and the glandular architecture. 3DCT performed especially with cone-beam CT following injection of the contrast medium into the ductal system without intravenous injection of contrast can provide images similar to or better than conventional sialography and is often referred to as CT sialography. MR Sialography, by contrast, delineates the ductal system of the gland without injection of ductal/intravenous contrast by utilizing the highly fluid-sensitive sequences similar to that used for magnetic resonance cholangiopancreatography (MRCP). MR

Sialography can be performed for patients with acute sialadenitis. Prior administration of a sialogogue agent may improve ductal visualization in MR Sialography. MR Sialography has poor spatial resolution as compared to conventional sialography⁵⁻⁷.

Ultrasonography: It is an ideal first line investigatory imaging modality for major salivary glands. It is useful to investigate the pathologies intrinsic and extrinsic to the salivary glands. Since it doesn't use ionizing radiation, it is an appropriate chairside procedure to detect the presence of salivary glandular pathology. Salivary calculi can be detected with great accuracy using this modality. It can be combined with FNAC to diagnose salivary glandular diseases. Bettina Sievert et.al in 2004, have documented the utility and safety of Ultrasound Guided Fine Needle Aspiration of Salivary gland masses and found the sensitivity of this modality to be 93.7%. Other studies have given a sensitivity values of 80% and specificity values of 95% for FNAC in parotid glandular lesions. A non-diagnostic rate of 10% is documented by some studies. Fine needle aspiration biopsy (FNAB) is an alternative modality to FNAC in diagnosing salivary gland diseases. Witt et al. through a systematic review and meta-analysis found the sensitivity values of FNAB to be 96% (95% confidence interval (CI) = 87–99%) and the specificity values were found to be 100% (95% CI = 84–100). Colour Doppler technique helps in the diagnosis of salivary gland diseases by assessing the vascularity of the lesion. The malignant salivary gland tumours tend to be more vascular than the benign salivary gland tumours. Pleomorphic adenoma, the commonest salivary gland neoplasm, is characterised by peripheral vascularity with central hypovascular area. $RI > 0.7$ and $PI > 1.2$ along with $PSV > 44.3$ cm/s, ill-defined margins, nodal involvement with central vascularity are highly indicative of a malignant salivary gland lesion^{8,9}.

CT and MRI: CT or MRI is useful for determining the extent of large tumours and for evaluating extra glandular extension. Additionally CT or MRI is useful in distinguishing an intraparotid deep lobe tumour from a parapharyngeal space tumour and for evaluation of cervical lymph node for metastasis. Non-Contrast CT might be enough in cases of sialolithiasis. CT scan is very useful in imaging palatal minor salivary gland neoplasms. For better recognition of the anatomy and identification of the extent of the lesion, these imaging procedures are performed after intravenous injection of contrast media. Sigal R et al. [1992] have documented the clinic-pathological correlation and MR Imaging in 27 cases with adenoid cystic carcinoma. Som PM et al. [1989] have documented high grade malignancies of parotid gland with MR Imaging. These studies have given a value of 73% accuracy for T2 weighted MR imaging to predict whether the mass is benign or malignant. Berg HM et al. [1986] have documented that CT is reliable in 60-70% of cases in predicting the histology of the lesion^{8, 10, 11}.

The differentiation of benign salivary gland tumors from malignant tumours is possible with Diffusion-weighted (DW) images and gadolinium-enhanced dynamic MR (Gd-MRI) imaging. The apparent diffusion coefficient (ADC) values can be calculated using DW images. The ADC values differ for different salivary gland neoplasms. The benign and malignant tumors can also be differentiated using 120 seconds as cut-off time to peak enhancement and a wash-out ratio of 30% with gadolinium-enhanced dynamic MRI. Low ADC values and plateau shaped time-intensity curve in dynamic Gd-MR is highly suggestive of malignancy. Proton MR Spectroscopy can also be used to differentiate benign from malignant tumours using choline/creatinine ratio. The choline/creatinine ratio is usually lower in malignant neoplasms than in benign neoplasms. MR microscopy is another imaging modality used in the imaging of parotid glands with smaller surface coils (usually less than 100mm in diameter) to obtain images having better spatial resolution for quantitative evaluation of patients with Sjogren's disease. The severity of this disease in the

parotid gland can be assessed by surveying the number of sialectatic foci, glandular fat quantification and the integrity of the glandular lobules¹¹⁻¹³.

Diagnostic sialendoscopy: It is an interventional diagnostic technique introduced in the 1990s to enable the oral diagnostician for directly visualizing the salivary duct lumen to detect calculi, mucosal plugs, polyps and foreign bodies. It helps the clinicians to view the ducts from outside. It's a minimally invasive procedure using a small caliber endoscope to visualize the salivary ductal system for any obstructive salivary gland disorders due to various causes. It is a chairside real-time investigation which can also be used for therapeutic purposes using various sialendoscopes namely the rigid, semi-rigid and flexible types. Since most of the glands removed because of sialolithiasis show normal glandular architecture, sialendoscopy is gaining popularity as the glands which were previously sacrificed can be saved using this technique¹⁴.

CONCLUSION

Ultrasound is an ideal first line imaging modality for major salivary gland disorders. When it is combined with FNAC, it is more reliable for diagnosing salivary glandular pathology. CT or MRI is better to delineate the extent and nature of the pathology in both major and minor salivary glandular diseases. Sialography can be used in combination with CT or MRI for diagnosing salivary glandular diseases whenever and wherever necessary¹⁵. Diagnostic sialendoscopy is a useful recent development in salivary gland imaging which can be used in obstructive salivary gland disorders

ACKNOWLEDGMENTS

None.

COMPETING INTERESTS

The author declares no competing interests with this case.

FUNDING SOURCES

None.

REFERENCES

- [1] Mohamed Abdulkader Riyaz. Current trends in Salivary Gland Imaging: A review. In: 28th Asia Pacific Congress on Dental and Oral Health; July10-12, 2017; Kuala Lumpur, Malaysia. Oral Health Dent Manag 2017, 16:3 (Suppl) DOI: 10.4172/2247-2452-C1-054.
- [2] G.S. Kumar. Orban's Oral histology and Embryology, 13th edition; Elsevier India, 2011.
- [3] Antonio Nanci. Tencate's Oral histology: Development, Structure, and Function, 9th edition; Elsevier Publications, 2018.
- [4] Oral Radiology: Principles and Interpretation by Stuart C. White & Michael J. Pharaoh: Sanjay Mallya; Ernest Lam, 8th edition. Published by Elsevier; 2018.
- [5] La'Porte SJ, Juttla JK, Lingam RK. Imaging the floor of the mouth and the sublingual space. Radio Graphics 2011; 31:1215-30.
- [6] Drage NA, Brown JE. Cone beam computed sialography of sialoliths. Dentomaxillofacial Radiology 2009;38:301-5.
- [7] Hugill J, Sala E, Hollingsworth KG, Lomas DJ. MR sialography: The effect of a sialogogue and ductal occlusion in volunteers. Br J Radiol 2008;967:583-6.
- [8] Yousem DM, Kraut MA, Chalian AA. Major salivary gland imaging. Radiology 2000;216:19-29.
- [9] Cho HW, Kim J, Choi J, Choi HS, Kim ES, Kim SH, et al. Sonographically Guided Fine-Needle Aspiration Biopsy of Major Salivary Gland Masses: A Review of 245 Cases. AJR Am J Roentgenol 2011;196:1160-63.
- [10] Liyanage SH, Spencer SP, Hogarth KM, Makdissi J. Imaging of salivary glands. Imaging 2007;19:14-27.
- [11] Rastogi R, Bhargava S, Mallarajapatna GJ, Singh SK. Pictorial essay: Salivary gland imaging. Indian J Radiol Imaging 2012;22:325-333.
- [12] King AD, Yeung DK, Ahuja AT, Tse GM, Yuen HY, Wong KT, et al. Salivary gland tumors at in vivo proton MR spectroscopy. Radiology 2005;237:563-9.
- [13] Takagi Y, Sumi M, Sumi T, Ichikawa Y, Nakamura T. MR Microscopy of the parotid glands in patients with Sjogren's syndrome: Quantitative MR diagnostic criteria. AJNR Am J Neuroradiol 2005;26:1207-14.
- [14] Atienza G, López-Cedrún JL. Management of obstructive salivary disorders by sialendoscopy: a systematic review. Br J Oral Maxillofac Surg. 2015;53:507-519.
- [15] S Jayachandran, Mohamed A Riyaz. Assessment of salivary gland enlargements with the aid of ultrasound-guided FNAC, CT, and MRI: A hospital based diagnostic study; JIAOMR, Year: 2009 | Volume: 21 | Issue: 4 | Page: 152-157.